DOI: 10.37988/1811-153X_2026_2_124

H.S.H. Al-Nuaimi [1],
PhD, researcher at the Department of Orthodontics, Pediatric and Special Care Dentistry
Z. bin Radzi [1],
PhD, professor of the Department of Orthodontics, Pediatric and Special Care Dentistry
A. Venugopal [2],
PhD, senior lecturer (orthodontics) at the Department of Oral Sciences
G. Battista [3],
DDS, lecturer
A. Campobasso [4],
PhD, professor of the Department of Clinical and Experimental Medicine

[1] University of Malaya, 50603, Kuala Lumpur, Malaysia
[2] University of Otago, 9016, Dunedin, New Zealand
[3] Private practice, 71122, Foggia, Italy
[4] University of Foggia, 71122, Foggia, Italy

A mini-implant-assisted derotation spring for correction of the eccentric rotation of the first premolar in a severely crowded arch: A case report

Annotation. A case report explores the effective use of a controlled derotation spring with temporary anchorage devices (TADs) to treat the severe rotation of a first premolar in a 23-year-old male. The treatment aimed to correct malocclusion and esthetic concerns by achieving stable derotation without compromising adjacent teeth. Over 18 months, this TAD-assisted approach successfully improved occlusion and tooth alignment. Three years of post-treatment records show that the results were well maintained. This case highlights the benefits of using TADs for precise and efficient orthodontic corrections.

Key words: TADS, rotation, cantilever spring, couple force

FOR CITATION:

Al-Nuaimi H.S.H., bin Radzi Z., Venugopal A., Battista G., Campobasso A. A mini-implant-assisted derotation spring for correction of the eccentric rotation of the first premolar in a severely crowded arch: A case report. *Clinical Dentistry (Russia)*. 2026; 29 (2): 124—134 (In Russian).
DOI: 10.37988/1811-153X_2026_2_124

Х.С.Х. Аль-Нуайми [1],
доктор наук, научный сотрудник кафедры ортодонтии, детской и специальной стоматологии
З. бин Радзи [1],
доктор наук, профессор кафедры ортодонтии, детской и специальной стоматологии
А. Венугопал [2],
доктор наук, старший преподаватель ортодонтии кафедры стоматологических наук
Г. Баттиста [3],
доктор стоматологических наук, преподаватель
А. Кампобассо [4],
доктор наук, профессор кафедры клинической и экспериментальной медицины

[1] Малайский университет, 50603, Куала-Лумпур, Малайзия
[2] Университет Отаго, 9016, Данидин, Новая Зеландия
[3] Частная практика, 71122, Фоджа, Италия
[4] Университет Фоджи, 71122, Фоджа, Италия

Пружина с мини-имплантатами для исправления поворота со смещением центра первого премоляра в сильно скученном зубном ряду: клинический случай

Аннотация. В клиническом случае рассматривается эффективное использование пружины с контролируемым поворотом и временными анкерными устройствами (TAD) для лечения выраженной ротации первого премоляра у 23-летнего мужчины. Целью лечения было исправление аномалии прикуса и эстетических проблем путем достижения стабильной деротации без ущерба для соседних зубов. В течение 18 месяцев этот подход с использованием TAD успешно улучшил прикус и выравнивание зубов. Результаты трехлетнего наблюдения подтверждают стабильность достигнутых изменений. Этот случай подчеркивает преимущества использования TAD для точных и эффективных ортодонтических коррекций.

Ключевые слова: TADs, ротация, консольная пружина, пара сил

ДЛЯ ЦИТИРОВАНИЯ:

Al-Nuaimi H.S.H., bin Radzi Z., Venugopal A., Battista G., Campobasso A. A mini-implant-assisted derotation spring for correction of the eccentric rotation of the first premolar in a severely crowded arch: A case report. — *Клиническая стоматология*. — 2026; 29 (2): 124—134.
DOI: 10.37988/1811-153X_2026_2_124

INTRODUCTION

Rotation is the term used to describe the intra-alveolar movement of a tooth along its longitudinal axis, whether it is mesiolingual or distolingual [1]. It can be classified as centric rotation (only rotation around the long axis where the angulation of the tooth's long axis remains unaltered), eccentric rotation (with tipping of the tooth), and pure rotation (if the body rotates about its center of resistance). This classification is based on the displacement along its longitudinal axis. Clinically, the rotated teeth are mostly correlated with malocclusion and could increase the possibility

of relapse after orthodontic treatment [2]. Additionally, rotated teeth can also lead to problems with bite alignment and overall dental health.

Tooth rotation is a kind of malocclusion that mostly needs orthodontic treatment. Rotated premolars not only affect occlusion but can also impact dental aesthetics. Correcting premolar rotation early in fixed orthodontic treatment is crucial, as it helps create space that can be used to relieve anterior crowding [3].

Derotating such teeth requires controlled mechanics, applying equal and opposite forces to achieve pure rotational movement [4]. Because they enable more accurate and consistent tooth movements, temporary anchoring devices (TADs) have greatly improved orthodontic treatment. Their strategic use enables orthodontists to expand treatment possibilities with improved efficiency [5].

Dental anthropologists thought that a congregation of genetics and environmental factors could lead to teeth rotation. These may include severe crowding, supernumerary teeth or odontomas, class II Division 2 malocclusion with lingually inclined central incisors, unilateral clefts where adjacent teeth are often rotated, over-retained deciduous teeth (as seen in this case report), ectopic canines, unerupted teeth positioned at the root base of fully erupted teeth, and scar tissue from trauma. Understanding these factors helps clinicians make informed decisions when managing such cases [6].

In this case report, we use a novel, well-controlled TAD-aided derotation spring to correct the severe eccentric rotation of the maxillary left first premolar.

CASE PRESENTATION

A 23-year-old male patient reported to the clinic with the chief complaint, "I don't like the appearance of my teeth and have difficulty chewing food."

On extraoral examination, he had normal vertical proportions of the face with a convex profile, competent lips, an obtuse nasolabial angle, and a limited exhibition of buccal corridors when smiling. The upper midline did not align with the facial midline and was displaced approximately 3 mm to the left (Fig. 1A).

Intraoral examination revealed caries in the lower second molar and a retained upper right deciduous molar. The incisor relationship was Class II Division 2 with a reduced overjet (1 mm) and an average overbite. There was some crowding in the maxillary arch, with a left lateral incisor that was palatally erupted and an upper right first premolar that was mesially tipped and rotated 90° to the side. The lower arch displayed slight crowding. The molar relationships on the right side were Class I, and on the left side was half-unit Class II. Furthermore, the canine relationships were classified as half-unit Class II on the left side and Class I on the right side (Fig. 1B, C).

The panoramic radiograph revealed an impacted upper right second premolar. The cephalometric radiographic analysis report states that the patient has a skeletal Class I relationship, hypodivergent facial type, and retroclination of both upper and lower incisors (Fig. 2, the Table).

Cephalometric analysis

Variable	Initial	Final	Norms [7]
SNA, °	81.1	81.2	81±3
SNB, °	78.2	78.3	78±3
ANB, °	2.9	2.9	3±2
MMPA, °	31	31	27±5
Face height ratio, %	54	54	55±2
SN to maxillary plane, °	8	8	8±3
Upper incisor to maxillary plane, °	107	112	109±6
Lower incisor to mandibular plane, °	96	96	93±6
Interincisal angle, °	123	137	135±10
Wit's appraisal, mm	−3	−1	0–1
Lower incisor to APo line, mm	4	2	1±2
Upper lip to E-line, mm	−5	−3	−3±2
Lower lip to E-line, mm	−2	−1	−1±2
Nasolabial angle, °	125	105	100±10

Remarks. SNA — Sella—nasion—point A; SNB — Sella—nasion—point B; ANB — point A—Nasion—point B; MMPA — Maxillomandibular plane angle.

Treatment plan and objective

The patient reveals a class I skeletal basis with a class II subdivision molar relationship, minimal crowding in the lower arch, and moderate crowding in the upper arch. Additionally, there was a hypodivergent facial pattern, retroclination of the upper incisors, a 90-degree eccentric rotation of the upper right first premolar, retention of the upper right deciduous molar and an impacted upper right second premolar.

The treatment plan proposed was:

- **Leveling and alignment of the upper and lower arches except for the upper right premolar and molars.**
- **Insertion of a mini-implant with a derotation spring in the buccal region between the upper canine and lateral incisor to facilitate the simultaneous derotation of the first premolar while leveling and straightening the arch, hence optimizing time efficiency.**
- **Remaining space closure.**
- **Following treatment completion, circumferential supracrestal fiberotomy on the upper right premolar followed by upper and lower vacuum-formed retainers.**

Two alternatives were proposed to achieve treatment goals:

1) The first option was to use a stiff 0.019×0.025" SS base arch wire after leveling and alignment in the maxillary arch. Reinforcing the anterior anchorage from the canine to canine (joining the segment using tight ligature ties) as well as a posterior anchorage (by joining first and second molars together using a ligated wire). These anchorage units would be used to derotate the premolar using power chains from the buccal surface of the 1st premolar to the hook between lateral and canine and from the lingual surface of the 1st premolars to the lingual surface of the 1st molar (using lingual buttons). Bite turbos would be placed to disocclude the premolars during the alignment phase.

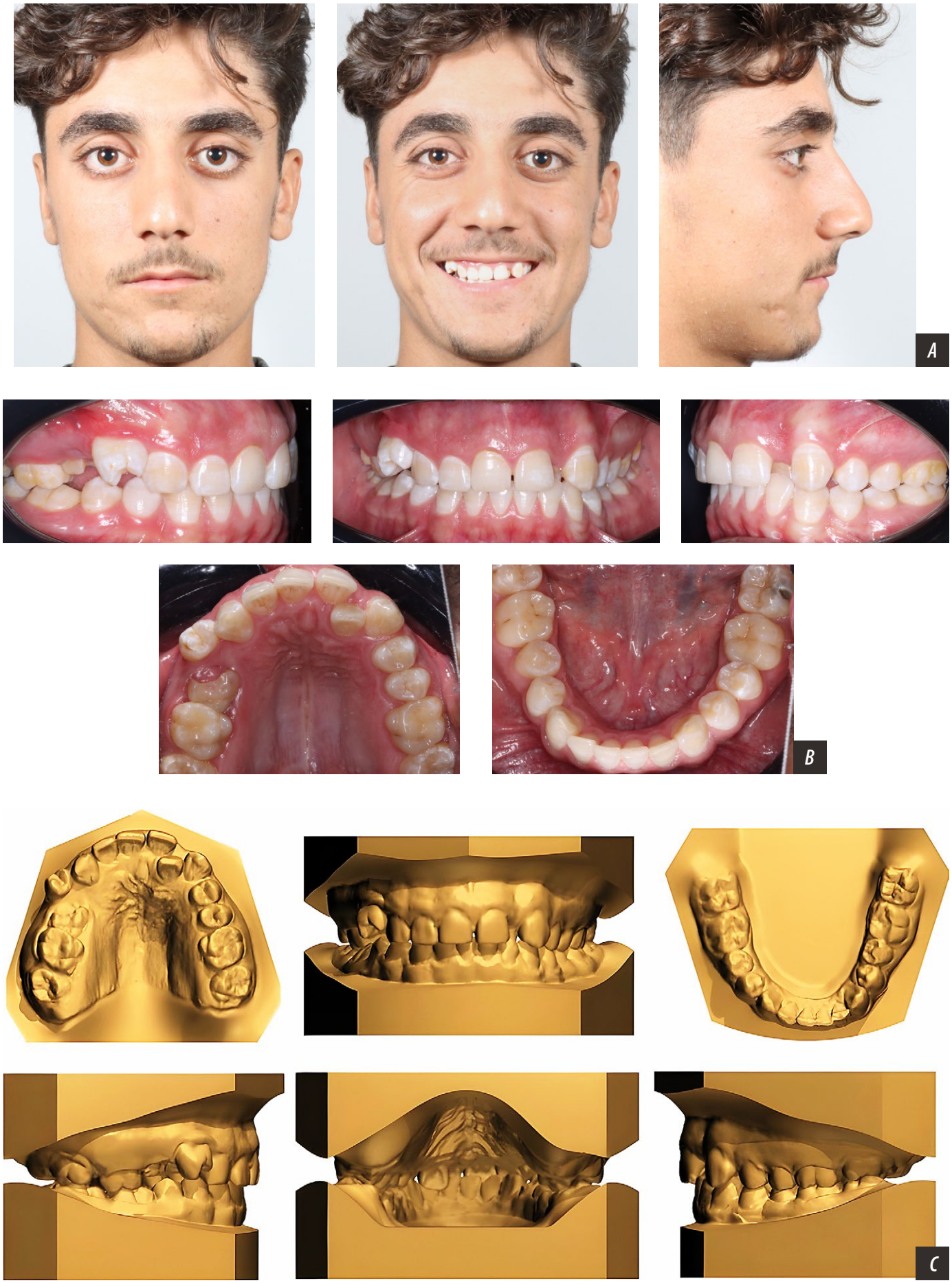

Fig. 1: A) Extra-oral photographs; B) Intra-oral photographs C) Initial digital models

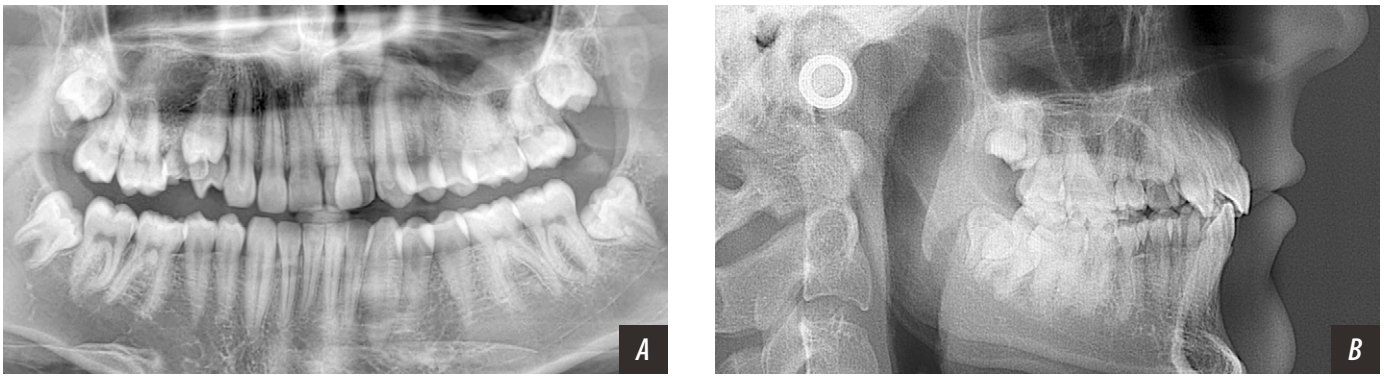

Fig. 2: A) Panoramic radiograph; B) Teleradiograph

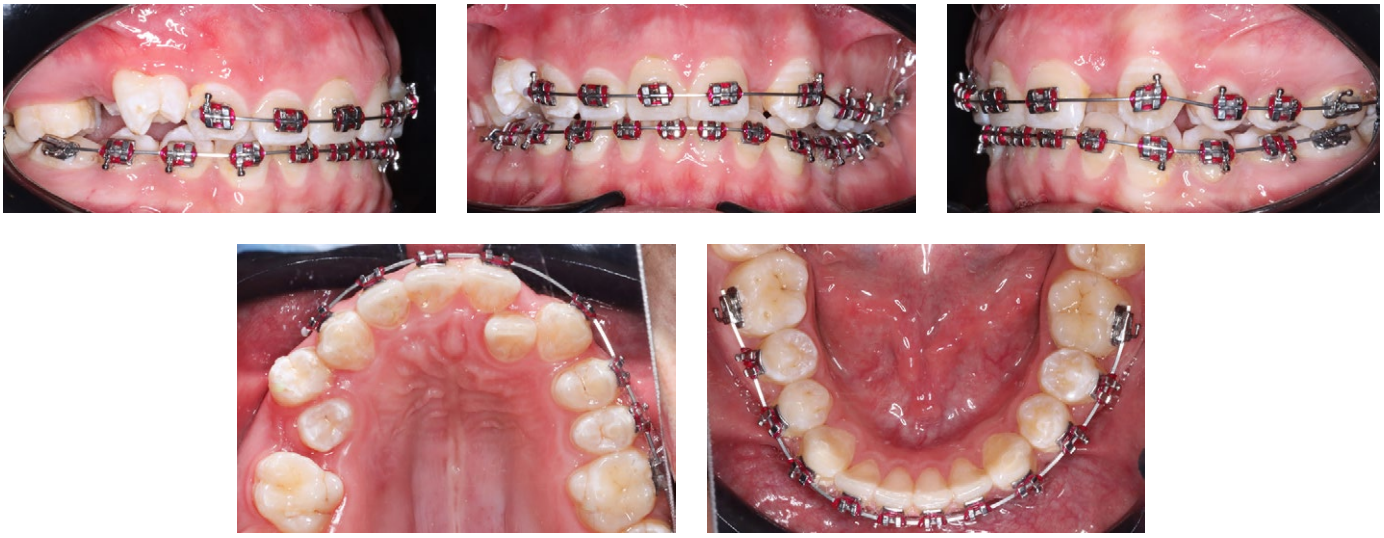

Fig. 3. Fixed orthodontic appliance (MBT, 0.022-inch slot, Dentaurum, Germany) was bonded, except for the upper right premolars and molars. Leveling and alignment started with a 0.014" NiTi archwire, progressing through a sequence to a 0.019×0.025" stainless-steel archwire

2) The second option was to again use a stiff 0.019×0.025" SS wire as the base arch wire. The anterior anchorage would be the same as the first option, but in this case, the posterior anchorage would be reinforced using a Transpalatal arch bonded to the first maxillary molars. The derotation would be carried out using similar biomechanics to the first option.

Unfortunately, used any of these previous mentioned methods will lead to fenestration, dehiscence and getting out the buccal root out of the alveolar bone, due to loss of palatal torque control mechanics during rotation. Moreover, using TADs as anchorage will reduce the unwanted teeth movement either posterior or anterior anchorage teeth, also, reduce the treatment time.

Treatment progress

Extraction of the upper right second deciduous molar was followed by placement of a fixed orthodontic appliance (MBT, slot 0.022-inch, Dentaurum, Germany) on the upper and lower arches except for the upper right premolar and molars to make space for the rotated premolars and give enough time for spontaneous eruption of the impacted upper right 2nd premolar. Leveling and alignment were started on 0.014" NiTi archwire and followed by a sequence of wires — 0.016", 0.018", and 0.016×0.022" NiTi and finally 0.019×0.025" SS archwire (Fig. 3). A novel controlled derotation spring was fabricated in such a way that it contained pre-adjusted 1st, 2nd, and 3rd order bends. The spring was fabricated using 0.016×0.022" SS with a helix measuring 1.5 mm in diameter (Fig. 4). The goal was to use this spring to help in derotation of the 1st premolar without causing any fenestration

Fig. 4. A controlled derotation spring was fabricated with pre-adjusted 1st, 2nd, and 3rd order wire bends (0.016×0.022" with a 1.5 mm diameter coil)

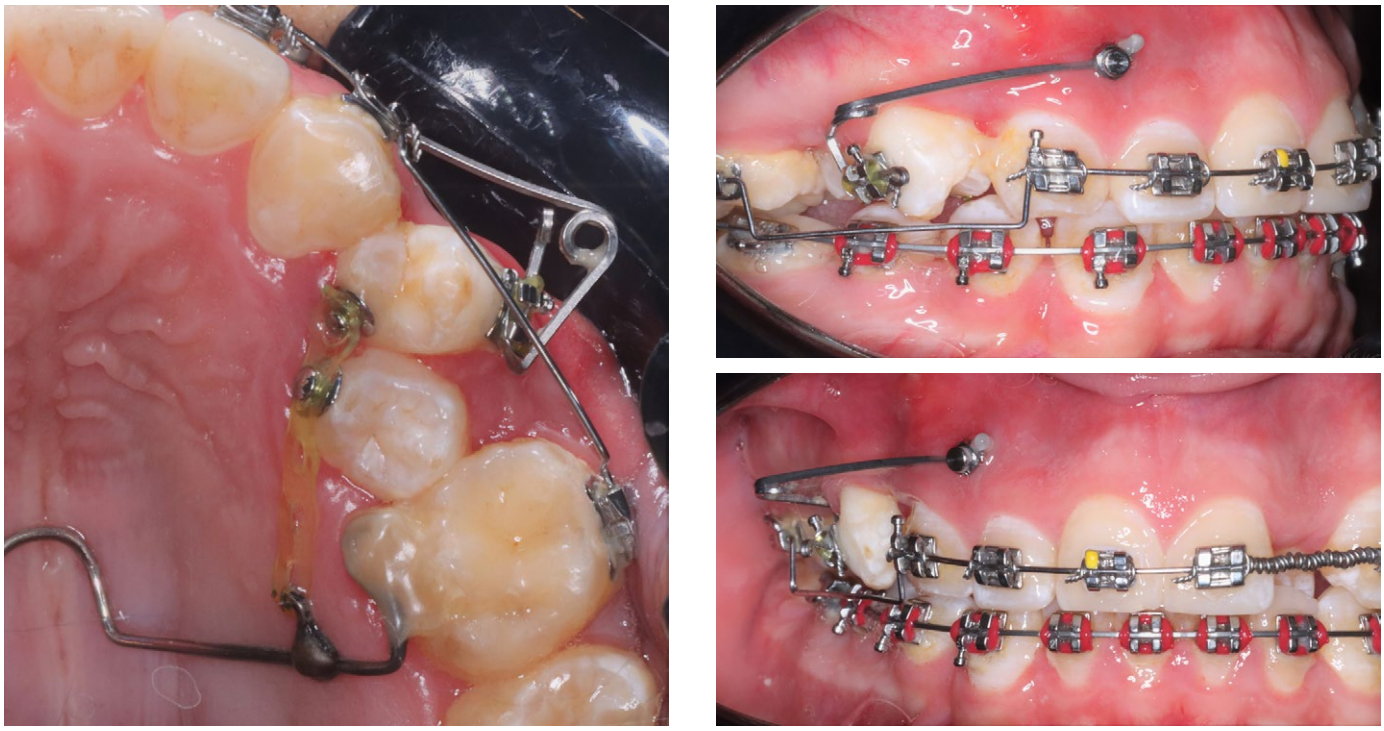

Fig. 5. The spring wire was connected to the miniscrew, activated by withdrawing the wire and cinching it back around the TADs' head (2 mm/month)

or dehiscence of the roots during rotation as it was tipped and nearly out of the arch. The spring was inserted into the TAD hole (1.6×8 mm; Dentaurum, Germany) placed between the upper right canine and lateral incisor (Fig. 5).

Fig. 6. Two lingual buttons were placed on the premolars and attached to a power chain (changed every two weeks) with a transpalatal arch (TPA) attached by composite restoration on lingual surface of 1st molars, to aid in derotation

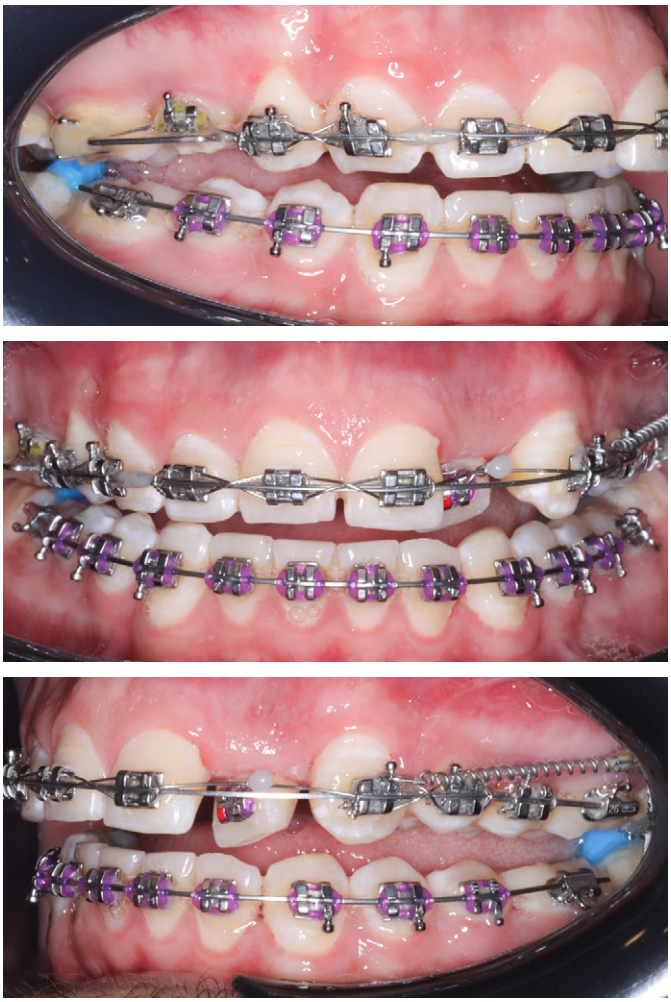

Fig. 7. After derotation, the second premolar was retracted using piggy-back mechanics, and an infra-zygomatic miniscrew was placed for distalizing the posterior segment using a NiTi closing coil from the miniscrew to canine hook

Activation of the spring

The spring was activated by pulling the wire distal from the TAD slot and cinching the wire distal to the TAD to generate mesio-palatal rotation on the arm that engages onto the bracket on the first premolar. A palatal root torque on the spring section that engages the first premolar bracket helps with keeping the roots in the bone while being derotated. Two lingual buttons are bonded on the lingual surface of both premolars, and a power chain runs from both to a hook soldered on a TPA figure to generate the desired couple (Fig. 6).

After derotation, piggyback mechanics was used to get the upper right 2nd premolar into the arch (Fig. 7), and at the same time an infrazygomatic mini-implant 2×12 mm (Dentaurum) was placed on the maxillary left side with a NiTi closed coil spring from the TAD to the canine hook for distalization of the posterior segment, providing enough space for the correction of the palatally displaced upper left lateral incisor. The bracket on the lateral incisor was inverted to generate increased labial root torque (Fig. 8).

The remaining space after premolar alignment was carefully closed, enhancing the treatment of the anterior overbite. To establish good occlusion, inter-arch maxillomandibular elastics were used between the upper and lower premolars and first molars (1/4", medium (4.5 oz), Orthometric, USA). Following the successful establishment of the occlusion, as depicted in fig. 9, the permanent appliance was removed. Circumferential supracrustal fiberotomy (CSF) technique was applied on the first and second upper right premolars to reduce the risk of relapse.

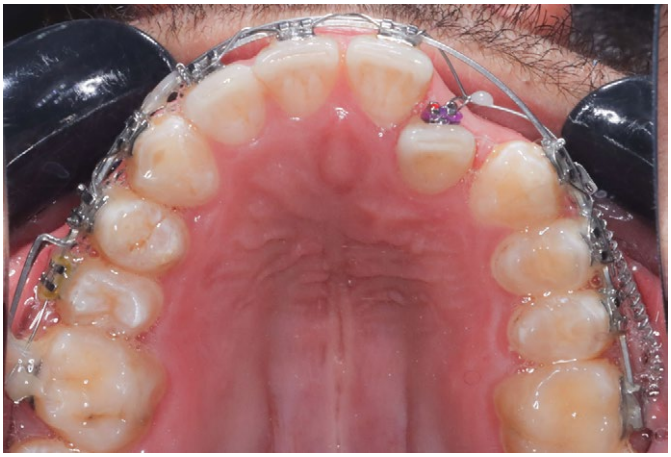

Fig. 8. The bracket on the lateral incisor was inverted upside down for add more buccal root torque during retraction and finishing stage, and a Peggy-back mechanics was used also for retraction

Fig. 9. After derotation, the buttons were removed, and brackets were bonded on the second premolars. The residual space left after premolar alignment was eventually closed and was helpful in the correction of the anterior deep bite

RESULTS

The orthodontic therapy concluded in 18 months. A Class I molar and canine relationship was established on both sides, characterized by a very good overbite, overjet, well-established incisor inclinations, and excellent alignment of teeth. The upper and lower midlines converged toward the conclusion of treatment. The upper right first and

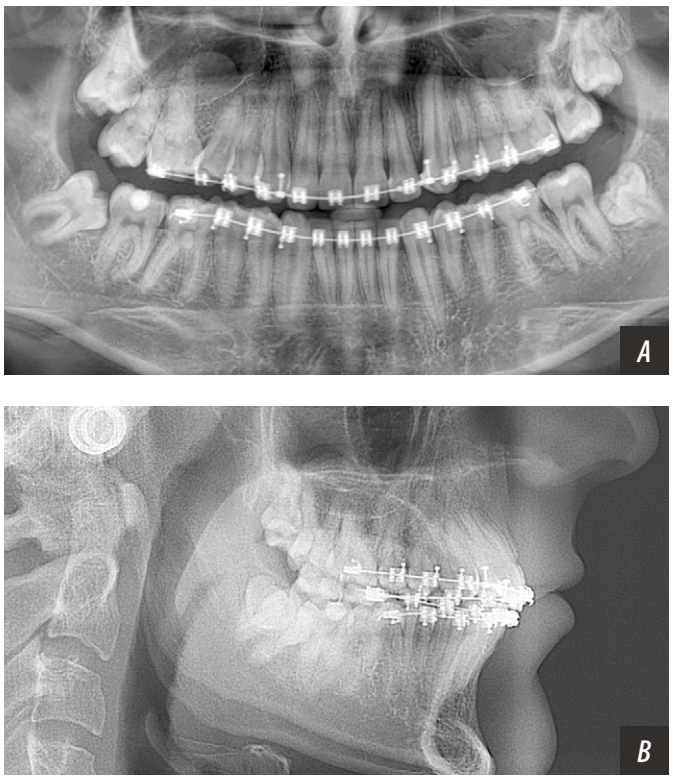

Fig. 10. Final panoramic radiograph and teleradiograph before debonding

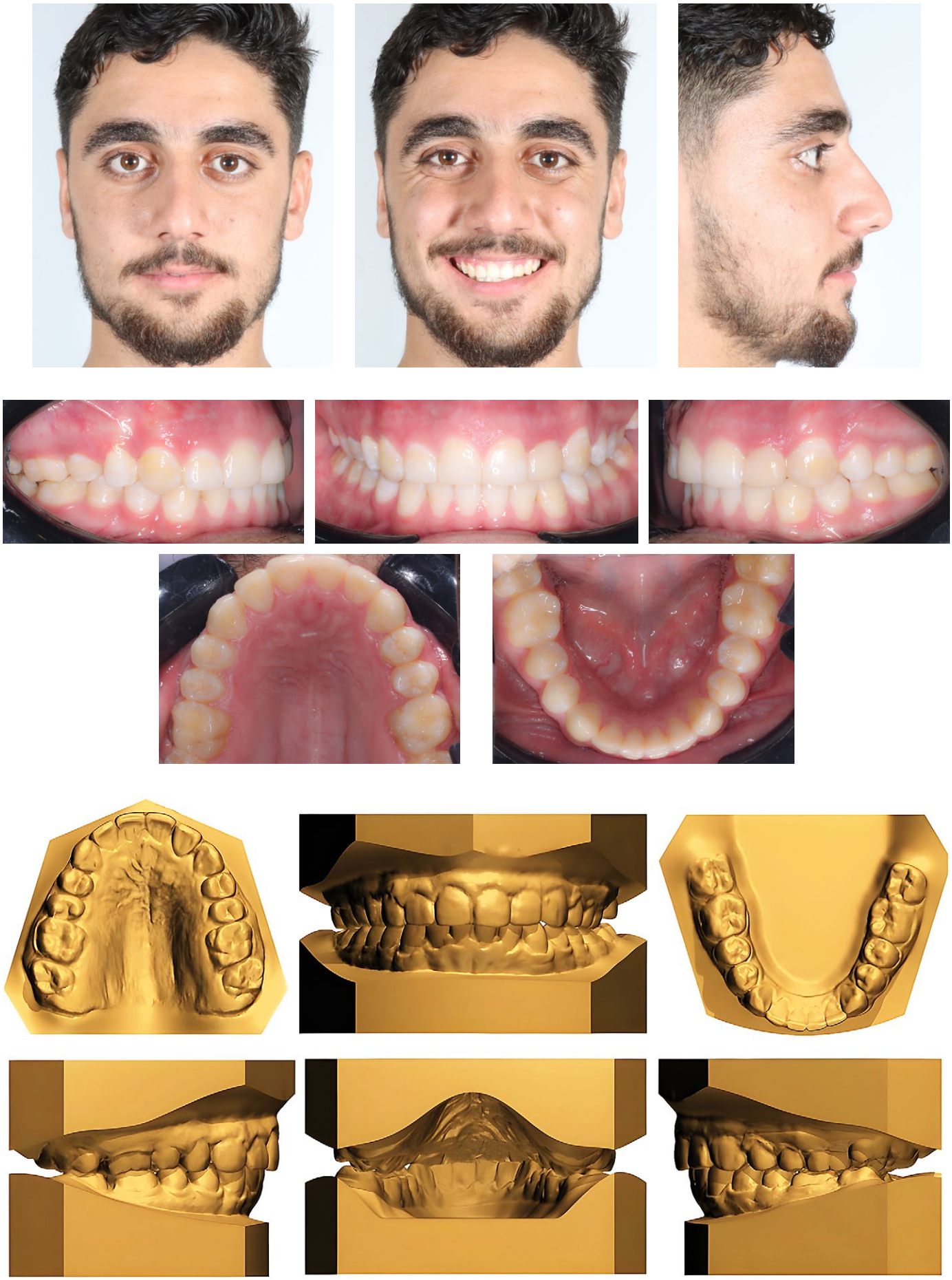

Fig. 11. Post-treatment record after debonding

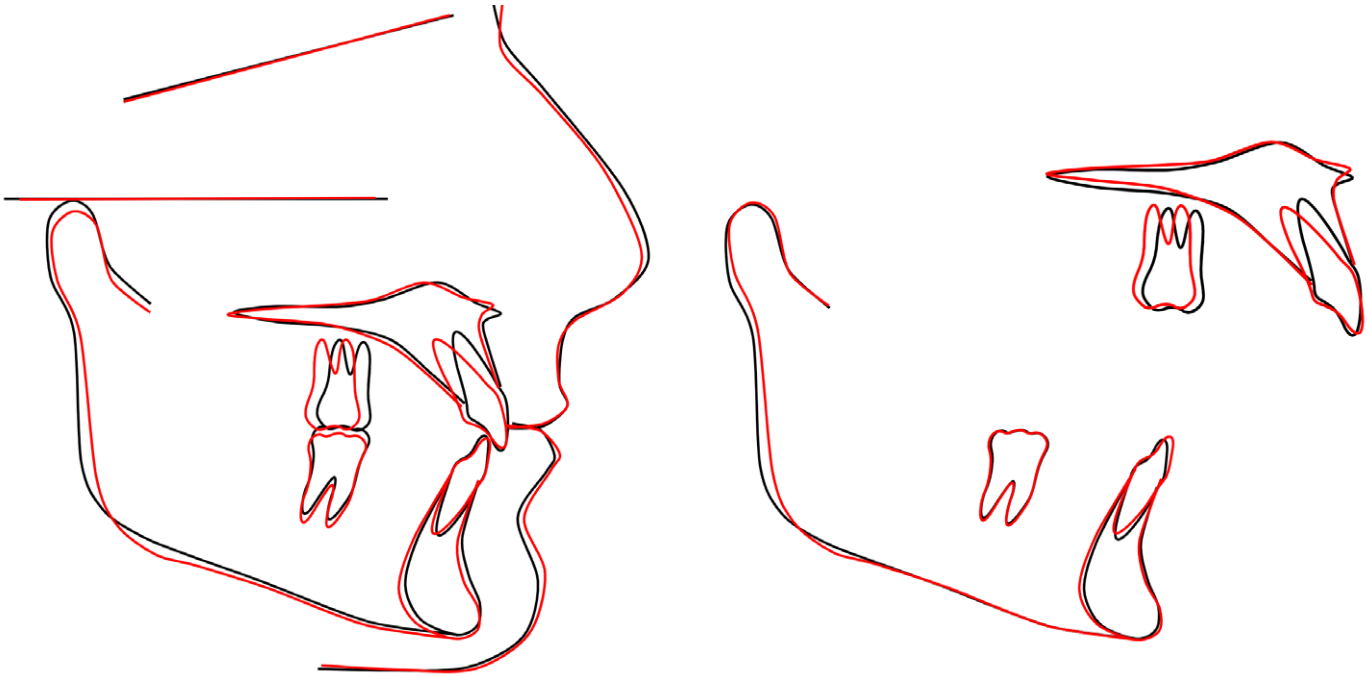

Fig. 12. Initial (red) and final (black) radiograph superimpositions

second premolars were derotated using a controlled derotation spring aided by TADs, while the subdivision and palatally displaced upper left lateral incisor were corrected using a single IZC screw-aided distalization (Fig. 10—12, see the Table). Circumferential supracrestal fiberotomy was executed on the derotated premolars to reduce the likelihood of relapse (Fig. 13).

The results were maintained using a vacuum-formed retainer (VFR) for both upper and lower arches. The final case results and a follow-up after three years of treatment are shown in the post-treatment records (Fig. 14). Fig. 15 shows the final superimposition between initial and final upper digital models and mesh deviation analysis.

DISCUSSION

Rotation of teeth in the maxillary and mandibular arches

The teeth rotation in the upper and lower arches is the most common dental finding. The amount of rotation could range from a mild inclination around its longitudinal axis to a severe, pronounced axial rotation, usually ranging from 90 to 180° [7]. Both unilateral and bilateral rotations could be possible, and they may impact one or more teeth, encompassing multiple archways. The prevalence of teeth rotations was most common, and according to the literature, the frequencies varied among different populations [8].

In order to understand the exact causes of rotations, a multitude of theories have been suggested. The initial explanation that Moore offered was the "theory of axial gradients." According to this theory, a cell's metabolic rate during embryogenesis determines its polarity [9]. The pole with the highest metabolic rate forms the "tail, " whereas the other pole forms the head. The theory suggests that tooth rotations may be influenced by the metabolic rates of cells during embryonic development, leading to differences in polarity and subsequent positioning of the teeth. Additionally, other factors such as genetics, crowding, and abnormal tooth eruption patterns may also contribute to the occurrence of teeth rotations. The buccal rotation is the consequence of the lingual portion of the tooth germ developing at a faster rate than the buccal portion for an unknown reason [10]. However, this theory was ultimately disproven due to its inability to account for the 180° rotation of premolars.

Ectopic eruption was another common etiology that is induced by abnormal positioning of premolar tooth crypts and teeth arch discrepancy in the arch. Another similar explanation was the early loss of deciduous molars, which could affect the sequence of eruption of the permanent teeth [11]. If one or both primary molars were exfoliated

Fig. 13. Circumferential supracrustal fiberotomy (CSF) was performed on the first and second premolars to avoid any further chances of relapse.

prematurely, the permanent first molar will migrate mesially. So, a reduction in space could lead to premolars' inability to erupt normally; it may be a consequence of this. Furthermore, the second premolar could be rotated to 180° by the subsequent eruption and mesial migration of the second molar, following its eruption in a rotated position [12].

Severe rotations are most effectively managed using fixed appliances. The most encountered drawback is relapse, mainly due to the rebound of elastic fibers, particularly the supracrestal fibers. However, this issue can be effectively managed through precision or CSF [13].

Couple forces and their role in orthodontic rotation

Couples are a special type of moment. It results from two forces in opposing directions but with the same magnitudes in a non-coincidental line of action. The opposing directions of these forces with equal force magnitudes result in pure rotation of the tooth without translating; the moment of a couple is defined by the magnitude of the forces and the distance separating them [14]. In the couple system, the creation of a moment results in the additive effects of two forces acting on opposite sides of the center of resistance (Cres). They are considered subtractive when positioned on the same side of the Cres, causing a rotational force rather than a translational force. Couplings are commonly used in engineering to create torque or rotational motion without causing linear movement. The concept of couples is essential in understanding the mechanics of rigid bodies and structures [15].

TADs (temporary anchorage devices) are small screws that are temporarily fixed to the bone to provide anchorage for orthodontic treatment. By strategically placing TADs, orthodontists can achieve precise and controlled movement of teeth without unwanted side effects. TADs were inserted into the occlusal surface to minimize encroachment on the first premolar during derotation. This could result in disocclusion in the premolar area. Tooth structures experience displacement (unwanted angling motions) as a result of the stresses produced by bracket-wire interactions. According to a specially designed rotational spring, the TADs in this instance not only allowed for pure rotational movement but also served as anchorage, which shortened the whole treatment time [16].

Fig. 14. Post-treatment records after three years of follow-up

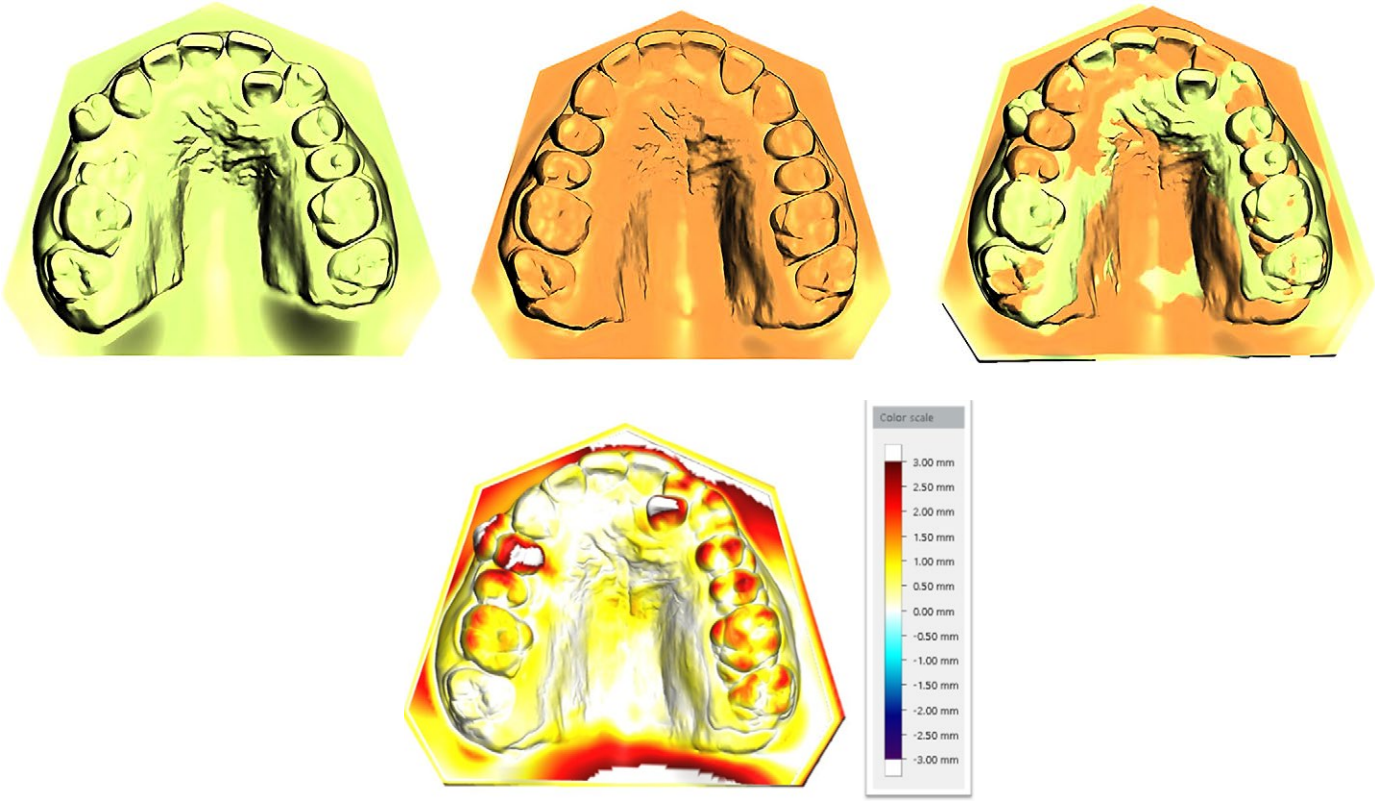

Fig. 15. Superimposition between initial and final upper digital models and mesh deviation analysis

Orthodontic relapse and retention strategies

Utilizing proper retention strategies, such as fixed retainers or clear aligners, can help maintain the alignment of teeth post-treatment and prevent relapse. Regular follow-up appointments with the orthodontist are also important to monitor any changes in tooth position and address them promptly. Tissue rebound and adverse developmental patterns are among the numerous factors that contribute to relapse. The periodontium's role in this process has been thoroughly examined due to the heightened risk of relapse in rotated teeth [17]. Rotated teeth are known to relapse more commonly, and the role of the periodontium has been extensively studied in this regard [18]. Reorientation and lack of reorganization of the supracrestal fibers are considered the main culprit for such relapse [17].

The main factors contributing to relapse include the lack of reorganization of supracrestal fibers and their reorientation. Edwards pioneered the surgical technique termed CSF for the purpose of severing periodontal fibers. The theory supporting CSF posits that this surgical intervention decreases the likelihood of relapses by relieving tension on the supra-alveolar fibers after derotation [17]. The theory behind this was that such a surgery would relieve the tension on the supra-alveolar fibers after derotating a tooth, reducing the chances of relapse [18]. Even with long term retention using fixed retainers, these sets of fibers have poor reorientation or reorganizational capacity for a longer time, they can only slightly reorient and rearrange themselves. The effectiveness of CSF as a standard procedure for maintaining derotations has been corroborated by multiple studies, alongside other retentive measures [19].

CONCLUSION

A TAD-aided derotation spring was effectively utilized to correct a 90-degree rotated first premolar. Additionally, the application of sound biomechanics successfully addressed a Class II subdivision, facilitated the eruption of an impacted second premolar, and repositioned a palatally displaced lateral incisor.

Received: 16.01.2026
Accepted: 30.04.2026

REFERENCES:

1. **Lee J., Smyth R.** Use of a modified transpalatal arch to correct a severely rotated maxillary incisor in the mixed dentition: A case report. — *Cureus*. — 2025; 17 (11): e97199. PMID: 41426822
2. **Bayani S., Khoramian S.** Correction of a severely rotated maxillary central incisor with the Whip device. — *Int J Orthod Milwaukee*. — 2011; 22 (4): 13–6. PMID: 22360076
3. **Maboudi A., Fekrazad R., Moosazadeh M., Rouhaninezhad H., Mollaei M., Namdar P.** Comparing circumferential supracrestal fiberotomy with surgical scalpel versus photobiomodulation in orthodontic relapse reduction: A clinical trial. — *Photobiomodul Photomed Laser Surg*. — 2023; 41 (8): 408–414. PMID: 37579132

4. George B.M., Arya S., G S S., Bharadwaj K., N S V. Robotic archwire bending in orthodontics: A review of the literature. — *Cureus*. — 2024; 16 (3): e56611. PMID: 38646270
5. Özden S., Cicek O. Analysis of the effect of maxillary transverse deficiencies on permanent maxillary first molar rotations using 3D digital models. — *BMC Oral Health*. — 2025; 25 (1): 879. PMID: 40457301
6. Umalkar S.S., Jadhav V.V., Paul P., Reche A. Modern anchorage systems in orthodontics. — *Cureus*. — 2022; 14 (11): e31476. PMID: 36523709
7. Kadhim H.A., Azzawi A.M., Uraibi A.H., Hasan H.S. Iraqi adult cephalometric standards: An analytical approach. — *Asian Journal of Dental Sciences*. — 2020; 3 (1): 9–20.
8. Drenski Balija N., Aurer B., Meštrović S., Lapter Varga M. Prevalence of dental anomalies in orthodontic patients. — *Acta Stomatol Croat*. — 2022; 56 (1): 61–68. PMID: 35382486
9. AlHudaithi F.S., AlDuhayan N.A., AlJohani L.N., AlJohani S.N., AlQarni H.S., AlSawadi M.H. Prevalence of dental anomalies among orthodontic patients: A retrospective study in Saudi Arabia. — *Cureus*. — 2023; 15 (12): e49893. PMID: 38174162
10. Akitomo T., Tsuge Y., Mitsuhata C., Nomura R. A narrative review of the association between dental abnormalities and chemotherapy. — *J Clin Med*. — 2024; 13 (16): 4942. PMID: 39201084
11. Hlongwa P., Moshaoa M.A.L., Musemwa C., Khammissa R.A.G. Incidental pathologic findings from orthodontic pretreatment panoramic radiographs. — *Int J Environ Res Public Health*. — 2023; 20 (4): 3479. PMID: 36834172
12. Mereani S., Alotaibi A., Bokhari A. Orthodontic management of a rare incidence bilateral maxillary canine-first premolar transposition using fixed appliance. — *Case Rep Dent*. — 2022; 2022: 9973333. PMID: 35527724
13. Skaf Z., Nabbout F. Class II correction with microimplant supported molar distalization: A report of two cases. — *Case Rep Dent*. — 2022; 2022: 2679318. PMID: 35860214
14. Kawamura J., Park J.H., Kojima Y., Tamaya N., Kook Y.A., Kyung H.M., Chae J.M. Biomechanical analysis for total mesialization of the maxillary dentition: A finite element study. — *Am J Orthod Dentofacial Orthop*. — 2021; 159 (6): 790–798. PMID: 33736907
15. Pace A., Sandler J. TADs: an evolutionary road to success. — *Dent Update*. — 2014; 41 (3): 242–4, 247–9. PMID: 24839713
16. Littlewood S.J., Dalci O., Dolce C., Holliday L.S., Naraghi S. Orthodontic retention: what's on the horizon? —*Br Dent J*. — 2021; 230 (11): 760–764. PMID: 34117435
17. Kumar S.O., Srinidhi S., Visshishta J., Sirisha S., Ranganathan S., Priya K., Moulvi S., Mani B. Evaluation of orthodontic retention protocol among orthodontist and general dentist—A cross-sectional survey. — *J Pharm Bioallied Sci*. — 2024; 16 (Suppl 2): S1588–S1590. PMID: 38882740
18. Al-Jasser R., Al-Jewair T., Al-Rasheed A. One-year rotational relapse frequency following conventional circumferential supracrestal fiberotomy. — *World J Clin Cases*. — 2020; 8 (2): 284–293. PMID: 32047776
19. Hasan H.S., Kolemen A., Elkolaly M., Marya A., Gujjar S., Venugopal A. TAD's for the derotation of 90° rotated maxillary bicuspids. — *Case Rep Dent*. — 2021; 2021: 4285330. PMID: 34367699

Издательство «Человек», 2026 г.
120 страниц
ISBN: 978-5-93339-587-4

Учебное пособие «Отечественные материалы, используемые в клинике ортопедической стоматологии»

Выход в свет учебного пособия Ю.В. Алпатьевой «Отечественные материалы, используемые в клинике ортопедической стоматологии» (под редакцией профессора В.Н. Трезубова), является своевременным ответом на актуальную задачу импортозамещения в медицинском материаловедении.

В издании последовательно и детально охарактеризованы физико-химические, технологические, токсикологические и клинические свойства отечественных стоматологических материалов. В фокусе внимания — эластические оттискные массы («Белопринт», «Беласт»), термопластические композиции («Мастер»), базисные и эластичные полимеры («Белакрил», «Белфлекс»), керамика («Ультропалин»), цементы («Уницем», «Цемион»), формовочные («Белоформ»), моделировочные и абразивные средства. Отдельно представлены материалы для шинирования («Армосплинт») и 3D-печати («Нолатек» 3D LCD/DLP).

Издание предназначено для студентов стоматологических факультетов, ординаторов и врачей-стоматологов. Особую ценность пособию придает прямое сопоставление отечественных материалов с зарубежными аналогами.